

# Treatment of nonmelanotic hyperpigmentation with the Q-switched ruby laser

Petra Maria Becker-Wegerich, MD, Annegret Kuhn, MD, Lucy Malek, MD, Percy Lehmann, MD, Mosaad Megahed, MD, and Thomas Ruzicka, MD *Düsseldorf, Germany*

Hyperpigmentation of the skin is often refractory to conventional therapies, but has significant cosmetic implications if located on visible areas. Because laser systems are capable of removing pigment deposits caused by selective photothermolysis, we addressed the issue of whether the Q-switched ruby laser could be a useful alternative in the treatment of nonmelanotic hyperpigmented skin lesions. We report the successful treatment of a patient with hyperpigmentation caused by iatrogenic human herpesvirus 8-associated Kaposi's sarcoma and a patient with hyperpigmentation caused by long-term antimalarial therapy for cutaneous lupus erythematosus. In both patients, clinical lightening of the darkly pigmented lesions was seen after a single treatment, and a significant improvement was observed after 3 laser applications. The patients tolerated the laser therapy well without any short-term side effects and did not experience either scarring or considerable textural skin changes. Histologic examination was performed before and after laser treatment to confirm the reduction of the pigment deposits. Our data indicate that treatment of nonmelanotic skin hyperpigmentation with the Q-switched ruby laser might be a safe and powerful therapeutic method. (*J Am Acad Dermatol* 2000;43:272-4.)

**M**any skin conditions caused by infectious, medication-related, genetic, acquired, and postinflammatory factors are common causes for pigmentary abnormalities.<sup>1-3</sup> It is important to evaluate the distribution, arrangement, and intensity of the color change for early diagnosis and sufficient therapy. Various therapeutic modalities can be used to treat hyperpigmented skin lesions such as surgical excision, discontinuation of triggering factors, lightening with azelaic acid or hydroquinone creams, camouflaging, or chemical peeling. Because selective photothermolysis with laser systems such as Q-switched ruby (QSRL), alexandrite, neodymium:YAG, and pulsed-dye green light laser is capable of selectively removing pigment deposits,<sup>4,5</sup> we evaluated QSRL treatment as a useful alternative therapy in the management of hyperpigmentation caused by iatrogenic human herpesvirus 8-associated Kaposi's sarcoma (HHV8-KS) or antimalarial agents.<sup>6,7</sup> The

QSRL emits light in the red portion of the visible spectrum at a wavelength of 694 nm, which as been shown to be effective in the treatment of epidermal and dermal cutaneous lesions.<sup>8</sup>

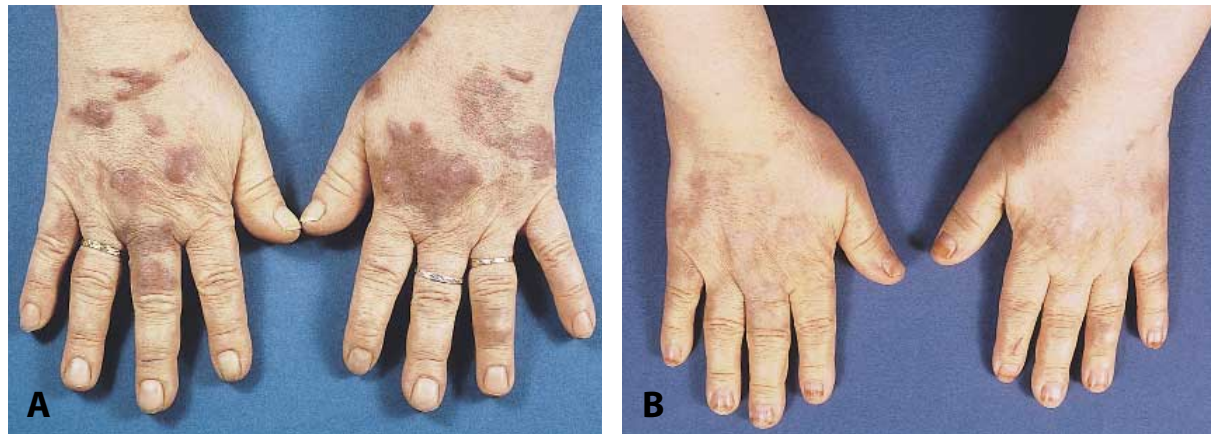The first patient was a 52-year-old Turkish woman (Fitzpatrick skin type III) with an 18-month history widespread HHV8-KS after systemic glucocorticoid therapy for sarcoidosis of the lung.<sup>9</sup> During the immunosuppression she experienced red-brown, livid hyperpigmented patches and tumors on the face, arms, back of the hands, fingers, and legs. After 5 monthly intravenous injections of liposomal doxorubicin (20 mg/cycle), only the facial patches disappeared completely; the tumors on the extremities cleared, leaving strong residual hyperpigmentation (Fig 1, A). Skin lesions on the back of the hands were treated 3 times at 6-week intervals with the QSRL (RubyStar, Aesculap-Meditec GmbH, Heroldsberg, Germany; 694 nm, 20 ns, 4 mm) at a fluence of 8 J/cm<sup>2</sup>. Multiple overlapping pulses were delivered to cover the lesions. Clinical lightening of the darkly pigmented skin lesions was perceived 6 weeks after the first treatment, and significant improvement was observed after 2 additional laser applications (Fig 1, B). Histologic findings of specimens from the right forearm revealed extensive basal melanin pigmentation as well as widespread deposition of hemosiderin in the mid and reticular dermis, which were both sig-

---

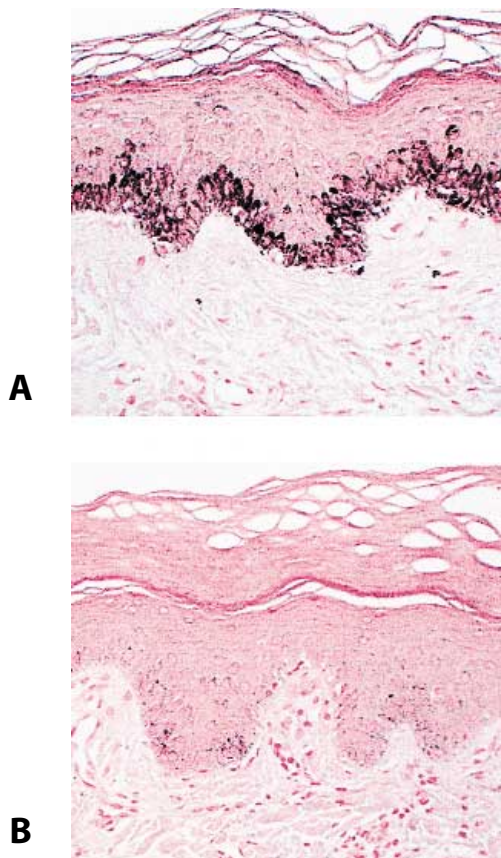
From the Department of Dermatology, Heinrich-Heine-University Düsseldorf.

Reprint requests: Petra Becker-Wegerich, MD, Department of Dermatology, Heinrich-Heine-University Düsseldorf, Moorenstrasse 5, 40225 Düsseldorf, Germany.

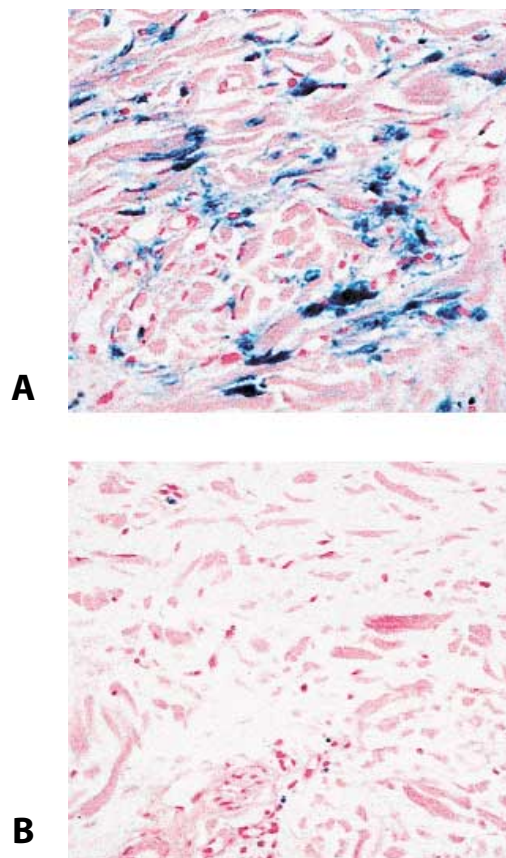
Copyright © 2000 by the American Academy of Dermatology, Inc. 0190-9622/2000/\$12.00 + 0 **16/1/105555**  
doi:10.1067/mjd.2000.105555



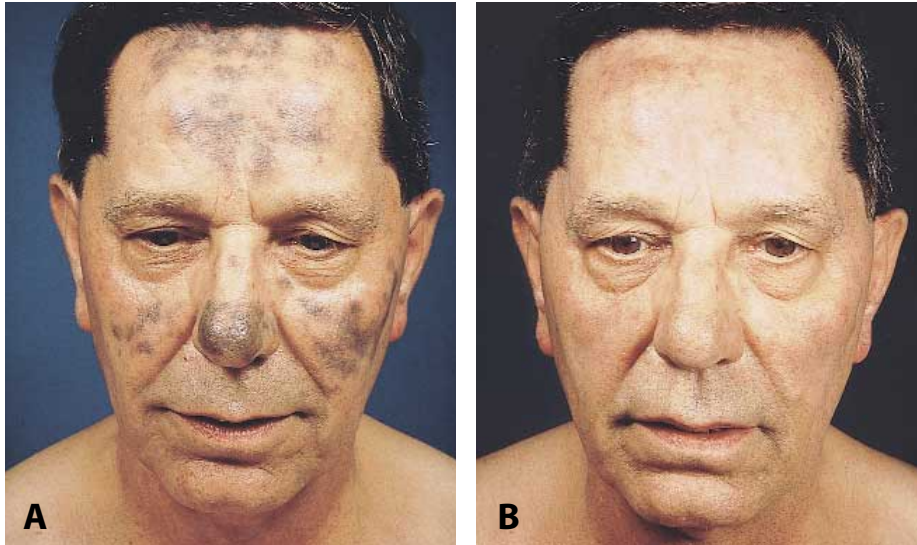**Fig 1. A,** Hyperpigmentation induced by antimalarial agents in 65-year-old patient with cutaneous lupus erythematosus. **B,** Significant improvement 6 weeks after 3 treatments with QSRL.



**Fig 2.** Photomicrograph of skin biopsy specimen taken from right forearm of first patient. (Masson-Hampel argentaffin stain; original magnification  $\times 200$ .) **A,** Before laser treatment extensive melanin pigmentation in basal layer of epidermis and in papillary dermis. **B,** After laser treatment almost complete disappearance of pigmentation.



**Fig 3.** Photomicrograph of skin biopsy specimen taken from right forearm of first patient. (Iron stain; original magnification  $\times 200$ .) **A,** Widespread hemosiderin deposits in dermis before laser treatment. **B,** Complete disappearance of deposits after laser treatment.



**Fig 4. A,** Hyperpigmentation of 52-year-old patient with iatrogenic HHV8-associated Kaposi's sarcoma. **B,** Almost complete remission 6 weeks after 3 treatments with QSRL.

nificantly reduced after treatment (Figs 2 and 3). Interestingly, both chromophores, melanin and hemosiderin, showed absorption by the same wavelength and fluence.

The second patient was a 65-year-old white man (Fitzpatrick skin type II) with a 5-year history of lupus erythematosus tumidus, a chronic form of cutaneous lupus erythematosus.<sup>10</sup> Although anti-malarial agents (chloroquine [Resochin] 250 mg/day for 1 year and hydroxychloroquine [Quensyl] 400 mg/day for an additional 2 years) had led to a complete clearing of the lupus erythematosus tumidus lesions on the face, he experienced dark gray–bluish hyperpigmentation during the therapy (Fig 4, A). The pigmented skin lesions were treated 3 times with the QSRL (RubyStar) at a fluence of 8 J/cm<sup>2</sup>. Each single treated lesion on the face was successfully lightened, and 6 weeks after the last laser application the hyperpigmentation was hardly visible (Fig 4, B). Before treatment, histologic findings of skin biopsy specimens taken from a pigmented lesion of the left cheek displayed extensive hemosiderin and melanin deposits in the papillary and mid dermis, which were greatly reduced after the therapy. Both patients tolerated the laser applications well without any short-term side effects, and neither experienced scarring or considerable textural changes of the skin.

Hyperpigmentation after chemotherapy of HHV8-KS or resulting from antimalarial agents is harmless, but the disfigurement it causes may be psychologically devastating to the affected patient.<sup>11</sup> Our data

indicate that the QSRL appears to be an appropriate method for the treatment of such hyperpigmentation of the skin; however, a correct diagnosis of the pigmented lesions before treatment is still absolutely necessary.<sup>12</sup>

#### REFERENCES

1. Kim NY, Pandya AG. Pigmentary diseases. *Med Clin North Am* 1998;82:1185-207.
2. Krebs A. Changes in skin color caused by drugs. *Schweiz Apoth Ztg* 1988;126:245-52.
3. Tannenbaum L, Tuffanelli DL. Antimalarial agents: chloroquine, hydroxychloroquine, quinacrine. *Arch Dermatol* 1980;116:587-91.
4. Hellwig S, Petzold D, König K, Raulin C. Current status of laser therapy in dermatology. *Hautarzt* 1998;49:690-704.
5. Spicer MS, Goldberg DJ. Lasers in dermatology. *J Am Acad Dermatol* 1996;34:1-25.
6. Rüdinger R. Ruby laser treatment for hyperpigmentation after cytotoxic therapy for AIDS-related Kaposi's sarcoma. *Br J Dermatol* 1998;138:924-7.
7. Wallace DJ. Antimalarial agents and lupus. *Rheum Dis Clin North Am* 1994;20:243-63.
8. Goldberg DJ. Benign pigmented lesions of the skin: treatment with the Q-switched ruby laser. *J Dermatol Surg Oncol* 1993;19:376-9.
9. Malek L, Rönnau A, Megahed M, Ruzicka T. HHV8-assozierte Kaposi-Sarkome. *Z Hautkr* 1999;74:374-5.
10. Kuhn A, Schuppe HC, Lehmann P, Goerz G, Ruzicka T. Cutaneous manifestations of lupus erythematosus: what is important for rheumatologists? *Rheumatol Eur* 1998;27:95-101.
11. Hohenleutner U, Michel S, Landthaler M. Rubinlaser: Medizin oder Kosmetik? *Z Hautkr* 1995;12:875-6.
12. Becker-Wegerich PM, Schulte K, Megahed M, Lehmann P, Fritsch C, Ruzicka T. Laser treatment of melanocytic skin lesions. *Munch Med Wochenschr* 1998;22:328-30.